

# Bladder stones associated with vesicovaginal fistula: A case report

*by* Francisca Francisca

---

**Submission date:** 04-Feb-2021 01:43AM (UTC+0530)

**Submission ID:** 1500930888

**File name:** Turnitin-108579\_BBB\_FVV\_Rev7\_EME.docx (211.17K)

**Word count:** 1917

**Character count:** 10992

## Bladder stones associated with vesicovaginal fistula: A case report

### Abstract

**INTRODUCTION:** The presentation of bladder stones is the most common manifestation of a lower urinary tract stone. In severe cases, it can cause pressure necrosis and lead to vesico-vaginal fistula (VVF). This case reports a female patient diagnosed with a bladder stone accompanied by VVF.

**PRESENTATION OF CASE:** A 56-year-old female came to the hospital with complaints of dysuria accompanied by continual urinary incontinence symptoms dating back about a month. During vaginal examination, we found a fistula and a stone. An ultrasound (US) showed a hyperechoic shadow measuring 1.27 x 1.36 cm in the vesica urinary and plain kidney, ureter, and bladder (KUB) x-ray showed the presence of a radiopaque shadow of about 7.5 x 5 cm in the pelvic area. This stone was removed through an open cystolithotomy. Intraoperatively, a fistula of about 1 cm in diameter was found in the trigonum close to the internal meatus. A fistula repair was performed immediately without complications, and the follow-up results were satisfactory.

**CONCLUSION:** The presentation of a bladder stone is an uncommon condition that can cause VVF. Therefore, it is important to pay attention to its clinical signs.

**Keywords:** Bladder Stone; vesicovaginal fistula; vesicovaginal fistula repair; cystolithotomy; case report.

## Introduction

Bladder stones are the most common manifestation of lower urinary tract stones, accounting for 5% of urinary stones and nearly 1.5% of all patients in the urology hospitalizations [1]. A vesico-vaginal fistula (VVF) is an abnormal communication between the bladder and the vagina that results in the unknown leakage of urine [2]. This condition is the most common type of urogenital fistula [1].

VVF resulting from giant bladder stones is uncommon; the bladder stone may put pressure on the bladder wall, causing tissue necrosis and eventually VVF [3]. Thus, this study reports the first case of bladder stone causing VVF in an elderly female in Indonesia. We reported the case in accordance with the SCARE 2018 guidelines [4].

## Case presentation

A 56-year-old female came to hospital with a complaint of pain during urination over the past month. There was also a complaint of continuous urinary incontinence, which had resulted in frequently wearing diapers over the last six months. She was embarrassed to spend time with others and thus had been isolating herself because she felt she smelled of urine. Since developing incontinence, the patient stated that she had not had sexual intercourse.

Meanwhile, the patient has a history of non-radiating low back pain. The patient claimed there was no blood or stones in her urine. Twenty years ago, her second pregnancy ended with a caesarean delivery, but a history of radiation was denied. Her menstruation was normal until her menopause began eight years ago. The patient had no significant record of previous medical history nor drug, cigarette or alcohol abuse.

On physical examination, the patient's general condition was good and vital signs were within normal limits with a body mass index (BMI) of 17.3 kg/m<sup>2</sup> (underweight). For the urology status, there were no abnormalities in the right or left costovertebral regions. Furthermore, there was no bladder distension. However, the vaginal examination revealed large stones protruding in the VVF area. Additionally, there was urine dribbling continually during a vaginal speculum examination. Based on laboratory results (routine blood), leucocytosis was found, and a leukocyte was discovered on urinalysis tests. Also, a urological ultrasound (USG) examination (Fig. 1) showed a hyperechoic shadow measuring 1.27 x 1.36 cm in the vesica urinary. The vesica urinary walls were thickened and had an irregular surface. The size of both kidneys were normal with no stones observed. A kidney, ureter, and bladder (KUB) x-ray showed the presence of a radiopaque shadow of about 7.5 x 5 cm in the pelvic area (Fig. 2).

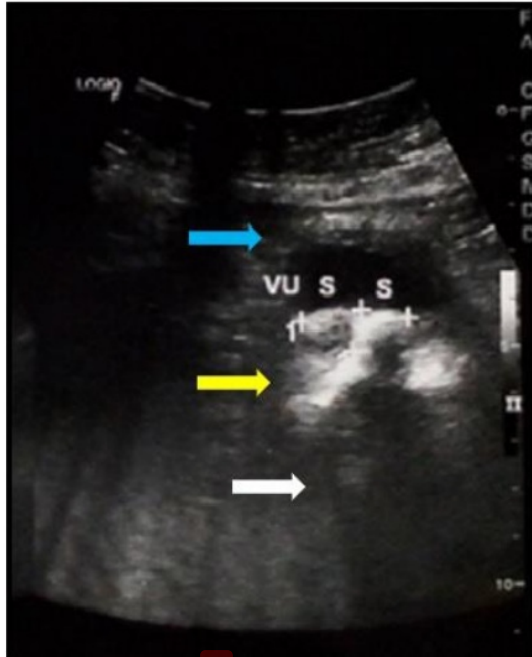
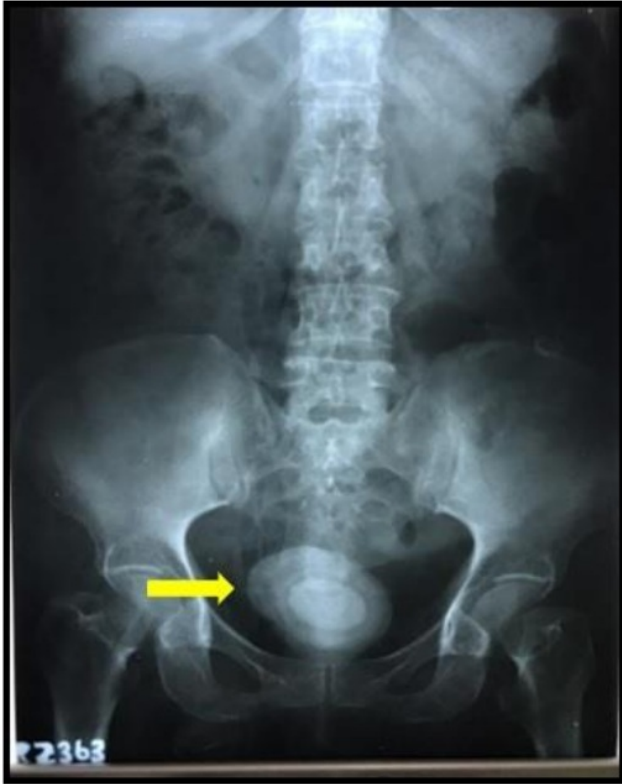

Figure 1. The results of ultrasonography showing a hyperechoic shadow in the bladder measuring 1.27 x 1.36 cm (yellow arrow) accompanied by echogenic shadow (white arrow). The bladder wall irregular and thickened (blue arrow).



9  
Figure 2. A kidney, ureter, and bladder (KUB) x-ray showing a radiopaque shadow in the pelvic area measuring about 7.5 cm.

Based on the patient's history and the physical and supporting examinations, we diagnosed this patient with bladder stones accompanied by VVF. We (an urologic surgeon and a general surgery resident) performed an open cystolithotomy and fistula repair under general anesthesia. The stone, which was approximately 8 x 5 x 5 cm, was successfully removed (Fig. 3) and a fistula hole of about 1 cm in diameter was found in the trigonum close to the internal meatus and subsequently repaired (Fig. 4).

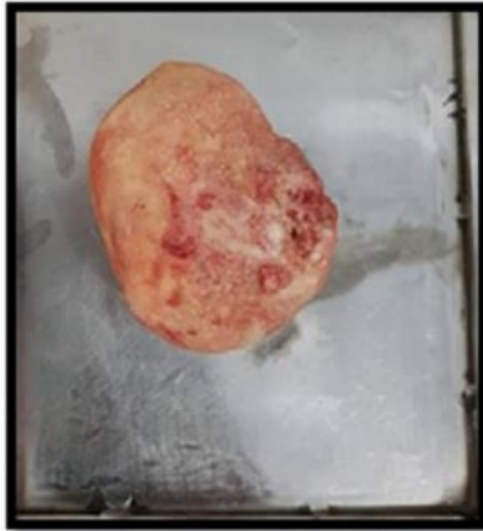


Figure 3. There were oval-shaped bladder stones sized approximately 8 x 5 x 5 cm.

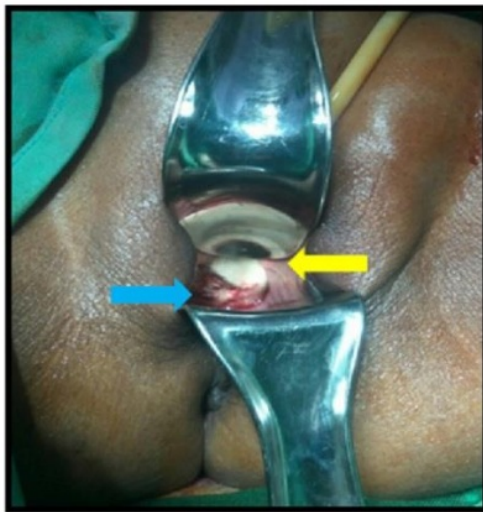

Figure 4. Vaginal examination revealed the existed of yellowish-white stones (marked with yellow arrow) and vesicovaginal fistulas (blue arrow).

Postoperatively, the patient was catheterized for fourteen days without the installation of peri-vesical drainage. The patient was advised to abstain from sexual intercourse for three months. At the patient follow-up at one, three, and six months postoperative, the results were satisfactory. She was voiding normally without incontinence and sexual function was significantly improved.

## Discussion

The risk factors of bladder stone formation are continuous stagnation of infected urine [5,6], urinary tract infections [7,8], foreign bodies [9,10], diet [11], and the debris desquamation of vaginal epithelium into the bladder [6]. In this case, primary bladder stones were accompanied by VVF. Its exact relationship with VVF is not known. In India, Mukerji et al. reported three cases of bladder stones, the first case with VVF and the rest with rectourethral fistula [3]. Meanwhile, Lavery et al., found that 1 of 160 case of VVF accompanied by bladder stone due to ulceration and erosion [12].

VVF has many etiologies, which may be acquired or congenital, and the major causes in developed countries are radiotherapy, pelvic region malignancy, and surgical procedures. Meanwhile, the most common cause developing countries is obstructed labor [3,13]. Foreign bodies are the most common cause, which is reported in about 10% of females with urinary disorders [14]. Meanwhile, other sources stated that VVF can be caused by pressure necrosis on the bladder wall [3]. In this study, the primary cause of the condition was pressure necrosis.

Clinical symptoms of bladder stones with VVF can include recurrent urinary tract infections, pyuria, suprapubic pain, severe swelling of the perineum, hematuria, or urinary incontinence. The severity of leakage can be reduced due to the "ball valve" effect caused by vesicle stones [13]. The patients in this study presented with the main symptoms of dysuria and continuous incontinence due to VVF.

Abdominal plain x-ray, ultrasonography (US), intravenous urography (IVU) and Multi-slice computed tomography (MSCT) are the most important tools for bladder stone evaluation and diagnosis. Most clinicians use KUB and US for initial examination [15].

Stone management depends on the size. It can be treated through cystolitholapaxy when it is less than 3 cm whereas open cystolithotomy is recommended when it is more than 3 cm. Existing literature suggested that handling bladder stones with VVF should follow a two-stage operation (Delayed Repair). The first stage is the removal of the stone with an endoscopic technique or open cystolithotomy, followed by VVF management for three months postoperative [5,6,16]. The rationale for the two-stage surgery is that the urine may contain infections or stones that can lead to inflammatory reactions in the bladder mucosa (edema) that will inhibit fistula healing [17].

The management of VVF operations is usually transvaginal or abdominal through a trans vesical approach. This treatment depends on the size and location of the fistula(e), the surgeon's experience, and the need for concurrent action [5,6]. Dalela et al. always performs the surgery by creating an omentum or flap Martius to strengthen the repair, and they succeeded in 84% of the cases [6].

In this study's patient, a one-stage operation (immediate repair) was performed because there were no signs of infection or edema. However, there was a possibility of fistula(e) repair failure in our patient, but at the postoperative follow-up, the results were satisfactory.

**Conclusion**

Bladder stone is an uncommon condition that can cause VVF. Therefore, it is important to pay attention to its clinical signs.

## References

- [1] A. Cardoso, A. Paes, T. Teixeira, Giant bladder stone in a patient with vesicovaginal fistula caused by bladder wall ischemia due to unassisted prolonged labor in the amazon jungle, *Int. J. Med. Rev. Case Reports.* 2 (2018) 82. <https://doi.org/10.5455/IJMRCR.giant-bladder-stone-vesicovaginal-fistula>.
- [2] I. Sunday-Adeoye, B. Daniyan, K. Ekwedigwe, D. Dantani, S. Uguru, A Review of the Management of Vesico-vaginal Fistula with Co-existing Bladder Calculi in South-East Nigeria, (2020).
- [3] A.C. Mukerji, B.C. Ghosh, M.M. Sharma, O.P. Taneja, Spontaneous urinary fistula caused by vesical calculus, *Br. J. Urol.* 42 (1970) 208–212. <https://doi.org/10.1111/j.1464-410X.1970.tb10024.x>.
- [4] R.A. Agha, M.R. Borrelli, R. Farwana, K. Koshy, A.J. Fowler, D.P. Orgill, H. Zhu, A. Alsawadi, A. Noureldin, A. Rao, A. Enam, A. Thoma, M. Bashashati, B. Vasudevan, A. Beamish, B. Challacombe, R.L. De Wilde, D. Machado-Aranda, D. Laskin, D. Muzumdar, A. D'cruz, T. Manning, D. Healy, D. Pagano, P. Goel, P. Ranganathan, P.S. Pai, S. Raja, M.H. Ather, H. Kadioažlu, I. Nixon, I. Mukherjee, J. Gómez Rivas, K. Raveendran, L. Derbyshire, M. Valmasoni, M. Chalkoo, N. Raison, O. Muensterer, P. Bradley, C. Roberto, R. Afifi, D. Rosin, R. Klappenbach, R. Wynn, S. Giordano, S. Basu, S. Surani, P. Suman, M. Thorat, V. Kasi, The SCARE 2018 statement: Updating consensus Surgical CAse REport (SCARE) guidelines, *Int. J. Surg.* 60 (2018) 132–136. <https://doi.org/10.1016/j.ijsu.2018.10.028>.
- [5] S. Rajaian, N.S. Kekre, Vesicovaginal fistula with large bladder calculus, *ANZ J. Surg.* 82 (2012) 278–279. <https://doi.org/10.1111/j.1445-2197.2012.06014.x>.
- [6] D. D., G. Apul, S. S.N., S. K.M., Vesical Calculi With Unrepaired Vesicovaginal Fistula: A Clinical Appraisal of an Uncommon Association, *J. Urol.* 170 (2003) 2206–2208. <https://doi.org/10.1097/01.ju.0000095503.76155.30>.
- [7] N. Segawa, Y. Katsuoka, K. Kaneda, [Vesico-vaginal fistula with a giant vesico-vaginal stone: a case report]., *Hinyokika Kyo.* 44 (1998) 517–520.
- [8] L. Yongzhi, Y. Shi, L. Jia, L. Yili, Z. Xingwang, G. Xue, Risk factors for urinary tract infection in patients with urolithiasis-primary report of a single center cohort, *BMC Urol.* 18 (2018) 45. <https://doi.org/10.1186/s12894-018-0359-y>.
- [9] F. Kamal, A.T.D. Clark, L.T. Lavallée, M. Roberts, J. Watterson, Intravesical foreign body-induced bladder calculi resulting in obstructive renal failure, *Can. Urol. Assoc. J.* 2 (2008) 546–548. <https://doi.org/10.5489/cuaj.927>.
- [10] M.A. Palinrungi, S. Syahrir, K. Kholis, Syarif, M. Faruk, Giant bladder stone formed around sewing-needle in childhood: A case report and literature review, *Urol. Case Reports.* 29 (2020)

101101. <https://doi.org/10.1016/j.eucr.2019.101101>.

- [11] İ.N. Tahtalı, T. Karataş, Giant bladder stone: A case report and review of the literature, *Turkish J. Urol.* 40 (2014) 189–191. <https://doi.org/10.5152/tud.2014.02603>.
- [12] D.W. Lavery, Vesico-vaginal fistulae; a report on the vaginal repair of 160 cases., *J. Obstet. Gynaecol. Br. Emp.* 62 (1955) 530–539. <https://doi.org/10.1111/j.1471-0528.1955.tb14785.x>.
- [13] M.-H. Cheng, H.-T. Chao, H.-C. Horng, M.-J. Hung, B.-S. Huang, P.-H. Wang, Vesical calculus associated with vesicovaginal fistula, *Gynecol. Minim. Invasive Ther.* 3 (2014) 23–25. <https://doi.org/https://doi.org/10.1016/j.gmit.2013.07.009>.
- [14] N. Radnia, T. Eftekhar, S. Sohbaty, T. Mohajery, Vesicovaginal Fistula Associated with a Vaginal Foreign Body in a 16-Year-Old Girl, *Nephrourol. Mon.* 10 (2018) e82387. <https://doi.org/10.5812/numonthly.82387>.
- [15] K.-S. Chow, C.-Y. Chou, A boy with a large bladder stone., *Pediatr. Neonatol.* 49 (2008) 150–153. [https://doi.org/10.1016/S1875-9572\(08\)60031-5](https://doi.org/10.1016/S1875-9572(08)60031-5).
- [16] T.P. Mahapatra, M.S. Rao, K. Rao, S.K. Sharma, S. Vaidyanathan, Vesical calculi associated with vesicovaginal fistulas: management considerations., *J. Urol.* 136 (1986) 94–95. [https://doi.org/10.1016/s0022-5347\(17\)44742-2](https://doi.org/10.1016/s0022-5347(17)44742-2).
- [17] S.N. Shephard, S.J. Lengmang, C. V Kirschner, Bladder stones in vesicovaginal fistula: is concurrent repair an option? Experience with 87 patients., *Int. Urogynecol. J.* 28 (2017) 569–574. <https://doi.org/10.1007/s00192-016-3142-1>.

# Bladder stones associated with vesicovaginal fistula: A case report

## ORIGINALITY REPORT

14%

SIMILARITY INDEX

7%

INTERNET SOURCES

13%

PUBLICATIONS

2%

STUDENT PAPERS

## PRIMARY SOURCES

- 1** Benway, Brian M., and Sam B. Bhayani. "Lower Urinary Tract Calculi", Campbell-Walsh Urology, 2012. 2%  
Publication
- 2** Ming-Huei Cheng, Hsiang-Tai Chao, Huann-Cheng Horng, Man-Jung Hung, Ben-Shian Huang, Peng-Hui Wang. "Vesical calculus associated with vesicovaginal fistula", Gynecology and Minimally Invasive Therapy, 2014 2%  
Publication
- 3** [sites.kowsarpub.com](http://sites.kowsarpub.com) 1%  
Internet Source
- 4** [pediatricurologycasereports.com](http://pediatricurologycasereports.com) 1%  
Internet Source
- 5** [www.omicsonline.org](http://www.omicsonline.org) 1%  
Internet Source
- 6** [www.doctors.org.cn](http://www.doctors.org.cn) 1%  
Internet Source

7	Sumadi Lukman Anwar, Ery Kus Dwianingsih, Widya Surya Avanti, Lina Choridah, Suwardjo, Teguh Aryandono. "Aggressive behavior of Her-2 positive colloid breast carcinoma: A case report in a metastatic breast cancer", Annals of Medicine and Surgery, 2020	1%
Publication		
8	Shanmugasundaram Rajaian. "Vesicovaginal fistula with large bladder calculus : Images for surgeons", ANZ Journal of Surgery, 04/2012	1%
Publication		
9	<a href="http://www.hindawi.com">www.hindawi.com</a>	1%
Internet Source		
10	<a href="http://archive.org">archive.org</a>	1%
Internet Source		
11	<a href="http://www.dovepress.com">www.dovepress.com</a>	1%
Internet Source		
12	Kuo-Shen Chow, Chieh-Yuan Chou. "A Boy with a Large Bladder Stone", Pediatrics & Neonatology, 2008	1%
Publication		
13	Songtao Xu, Weixin Sheng, Yufa Qiu, Jianguo Wang. "An Unusual Complication of Ventriculoperitoneal Shunt: Urinary Bladder Stone Case Report and Literature Review", Iranian Red Crescent Medical Journal, 2016	1%

14

A. C. MUKERJI. "SPONTANEOUS URINARY FISTULA CAUSED BY VESICAL CALCULUS",  
British Journal of Urology, 04/1970

Publication

---

1%

15

Clifford Wai, Amanda White. "Vesicovaginal  
Fistula", Current Women's Health Reviews,  
2006

Publication

---

<1%

---

Exclude quotes      Off

Exclude matches      Off

Exclude bibliography      On

# Bladder stones associated with vesicovaginal fistula: A case report

---

## GRADEMARK REPORT

---

FINAL GRADE

**/0**

GENERAL COMMENTS

**Instructor**

---

PAGE 1

---

PAGE 2

---

PAGE 3

---

PAGE 4

---

PAGE 5

---

PAGE 6

---

PAGE 7

---

PAGE 8

---

PAGE 9

---

PAGE 10

---